




Contents lists available at ScienceDirect

The Journal of Foot & Ankle Surgery

journal homepage: www.jfas.org

Original Research

A Multicenter Retrospective Review of Outcomes for Arthrodesis, Hemi-Metallic Joint Implant, and Resectional Arthroplasty in the Surgical Treatment of End-Stage Hallux Rigidus

Paul J. Kim, DPM, FACFAS¹, Daniel Hatch, DPM, FACFAS², Lawrence A. DiDomenico, DPM, FACFAS³, Michael S. Lee, DPM, FACFAS⁴, Bruce Kaczander, DPM, FACFAS⁵, Gary Count, DPM, FACFAS⁶, Marc Kravette, DPM, FACFAS⁷

¹ Associate Professor, Department of Plastic Surgery, Georgetown University Hospital, Washington, DC

² Private Practice, Foot and Ankle Center, Greeley, CO

³ Private Practice, Ankle and Foot Care Centers, Youngstown, OH

⁴ Private Practice, Capital Orthopedics and Sports Medicine, Clive, IA

⁵ Private Practice, Michigan Foot and Ankle Center, Southfield, MI

⁶ Private Practice, Scituate Podiatry Group, Inc., Scituate, MA

⁷ Surgeon, Department of Orthopedics, Virginia Mason Medical Center, Seattle, WA

ARTICLE INFO

Level of Clinical Evidence: 3

Keywords:

arthritis
bone
foot
joint replacement
metatarsal
phalanx
surgery
toe

ABSTRACT

This is a retrospective, multicenter study examining the long-term results for the treatment of end-stage hallux rigidus using 3 different surgical procedures. A total of 158 subjects (105 females and 53 males) were included in the present study. They had undergone 1 of the following surgical procedures: arthrodesis, hemi-implant, or resectional arthroplasty. The long-term results for the subjective assessment of pain, function, and alignment, as well as objective radiographic and physical findings, were examined. The median interval to postoperative follow-up for the 3 procedure groups was 159 weeks. No statistically significant difference was found in age or the number of subjects included in the 3 treatment groups ($p = .11$ and $p = .16$, respectively). The body mass index was significantly different statistically among the 3 treatment groups, with the hemi-implant group representing a smaller body mass index compared with the other procedures ($p = .007$). No statistically significant difference was found in the subjective outcomes among the 3 treatment groups using the American College of Foot and Ankle Surgeons' First Metatarsophalangeal Joint and First Ray Scoring Scale (patient questionnaire) or the modified Hallux Metatarsophalangeal-Interphalangeal Scale of the American Orthopedic Foot and Ankle Society ($p = .64$ and $p = .14$, respectively). Furthermore, the correlation coefficient between the 2 subjective scoring scales was 0.78, statistically significant and reflecting a moderate to high correlation ($p < .001$). The results of the radiographic and clinical evaluation revealed that metatarsalgia was the most common finding for the arthrodesis group (9.8%), bony overgrowth into the joint for the hemi-implant group (28.3%), and floating hallux for the resectional arthroplasty group (30.9%). The results of our study suggest that all 3 surgical procedures are viable options for the treatment of end-stage hallux rigidus.

© 2011 by the American College of Foot and Ankle Surgeons. All rights reserved.

Hallux rigidus is a degenerative process that affects the integrity of the first metatarsophalangeal joint (MTPJ). Patients afflicted with this condition report pain during ambulation and in shoe gear (1). Clinically, a decrease or absence of range of motion, along with pain and/or

crepitus, is noted (2). Radiographically, typical joint destructive changes are identified, including narrowing and flattening of the joint space, subchondral sclerosis, cystic changes, joint debris, and dorsal spurring (2,3). Intraoperatively, a direct examination of the joint surfaces reveals denudation of cartilage, cystic changes to the surrounding bone, and periarticular osteophytic spurring. The lack of a cartilage interface is thought to be the cause of the pain experienced by those with this degenerative process.

Hallux rigidus is progressive and can be initiated by an acute traumatic event. However, the most common cause involves a biomechanical etiology (4). This can include increased pronatory

Financial Disclosure: None reported.

Conflict of Interest: None reported.

Address correspondence to: Paul J. Kim, DPM, FACFAS, Associate Professor, Department of Plastic Surgery, Georgetown University Hospital, 3800 Reservoir Road, NW, Washington, DC 20007-0469.

E-mail address: paul.j.kim@gunet.georgetown.edu (P.J. Kim).

forces, resulting in a decrease in the available range of motion at the first MTPJ, causing dorsal jamming experienced within the joint (5,6). Underlying anatomic variations, such as a long first metatarsal and tightness of the plantar fascia, can also potentiate this process. The repetitive traumatic process continues to destroy the cartilage within the joint, causing exposure of the underlying subchondral bone. The inability of the chondral surfaces of the joint to regenerate contributes to making this an irreversible process.

A variety of surgical treatment options are available for hallux rigidus once nonoperative methods have failed. The primary goal of surgical treatment of hallux rigidus is pain relief. The secondary goal is improvement in overall function. These surgical treatment options are largely dependent on the stage or grade of hallux rigidus; however, consensus is lacking regarding the most accurate classification system (7). The classification system proposed by Coughlin and Shurnas (8) systematically examines the range of motion, radiographic findings, and clinical findings to grade the hallux rigidus. This classification scale progresses from grade 0 to grade 4. With each advancing grade, the degree of degeneration of the first MTPJ increases. This classification system is widely accepted and hence was used in the present study to standardize our evaluation.

It is generally accepted that 2 broad categories of procedures exist for the surgical treatment of hallux rigidus. The first broad category is considered “joint sparing” procedures, which include cheilectomy, sesamoid excision, arthrodiastasis, and decompression osteotomy (9,10). As the name implies, these procedures attempt to maintain the integrity of the first MTPJ. This category of procedures is generally used for earlier stages of this degenerative process. The second category is considered “joint destructive” procedures, including joint fusion, joint replacement, and joint resection (Figs. 1 to 3) (9–11). This category of procedures eliminates the anatomic joint and is usually reserved for the end-stage of this disease process. This latter category was the focus of the present study.

Arthrodesis of the first MTPJ was initially reported by Broca (12) in 1852 and popularized by McKeever (13). This procedure of fusing the first MTPJ has been successfully used for decades (14–16). If fusion is achieved, the results of the procedure are long lasting. Although arthrodesis is typically used as a primary procedure for hallux rigidus, it has also been advocated as a salvage procedure for failed resectional arthroplasties (17–19).

Joint implant arthroplasty is a surgical technique involving the use of engineered materials placed into the first MTPJ, thereby creating an artificial joint. Swanson et al (20) popularized a single and double stemmed, hinged type silicone implant in the 1970s. These implants have evolved in materials and design over the decades. The materials used have included silicone, ceramics, polymers, and metal alloys. Hemi-implants (hemi-arthroplasty) are 1-piece constructs that are placed at the base of the proximal phalanx or the head of the first metatarsal. These types of implants have grown in popularity owing to their simple application and have yielded good results (21–23).

Resectional arthroplasty (Keller procedure), since its introduction to published studies in the early 1900s, has been used successfully for decades (24–26). Although this procedure has been modified over the years, it has been a viable surgical option for the treatment of hallux rigidus (27–29). This technique involves the resection of the base of the proximal phalanx of the hallux, thereby removing the degenerated joint interface.

Robust long-term studies examining the efficacy for the surgical treatment of end-stage hallux rigidus are lacking. There are conflicting and unclear published reports regarding arthrodesis, hemi-implant arthroplasty, and resectional arthroplasty. To our knowledge, no large, long-term published outcome studies have directly compared these 3 surgical techniques. The present study was a multicenter, retrospective, comparative study examining the

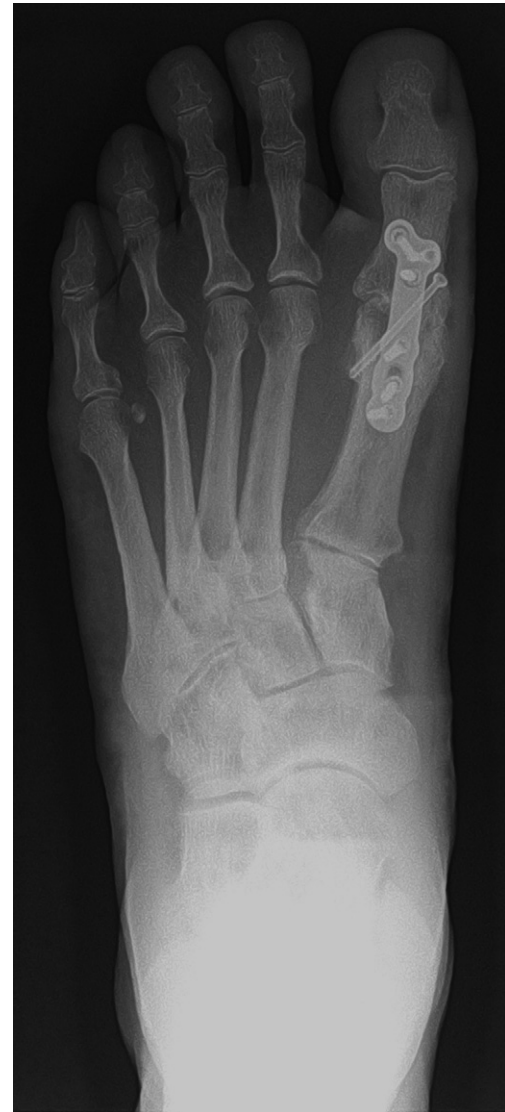

Fig. 1. Arthrodesis. Postoperative dorsal-plantar radiographic view demonstrating result of arthrodesis of first metatarsophalangeal joint using a plate and a single partially threaded cortical lag screw.

long-term outcomes of arthrodesis, hemi-metallic joint implants, and resectional arthroplasty in patients with end-stage hallux rigidus.

Patients and Methods

Investigative Sites

A general call for investigative site participation was conducted through print media and the website by the American College of Foot and Ankle Surgeons (ACFAS). The potential sites were required to meet the following criteria, outlined in the application: (1) 1-year contractual commitment to the study; (2) the investigator for each site must be a fellow or an associate of the ACFAS; (3) the investigator must have performed a minimum of 50 surgical procedures for the treatment of hallux rigidus; (4) the investigator must have performed all 3 procedures; and (5) the investigator must have a professional reputation for scholarly activity. Fourteen applications were reviewed by the study director (P.J.K.).

Five sites were initially selected to participate according to these criteria and their geographic location. An attempt was made to prevent regional clustering of investigative sites by selecting sites from different geographic regions across the United States. A formal statistical clustering prevention plan was not conducted. Within the first year of the study, 2 sites were withdrawn by the study director. One of these sites was

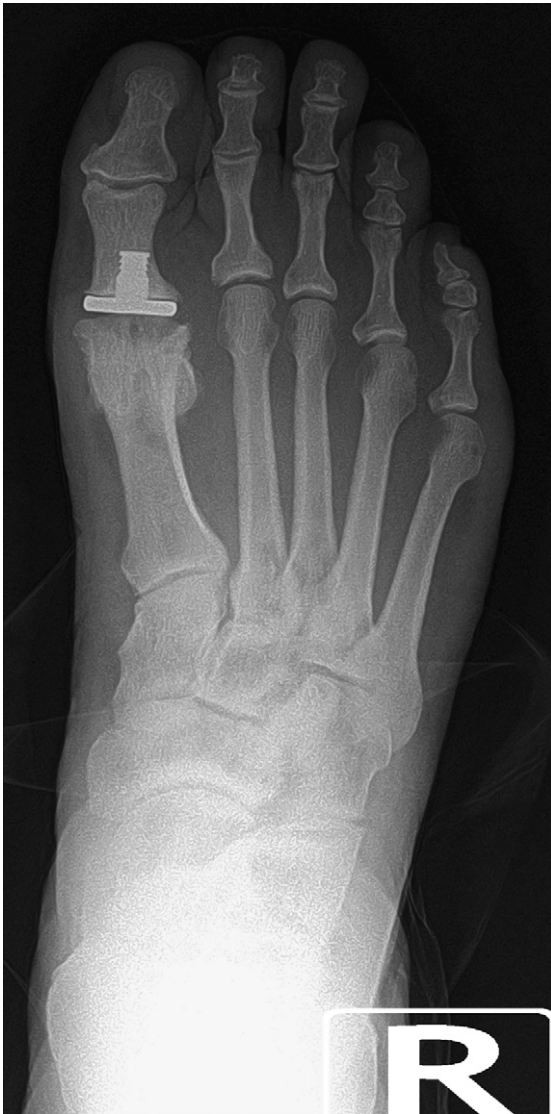

Fig. 2. Hemi-implant arthroplasty. Postoperative dorsal-plantar radiographic view demonstrating result of hemi-implant arthroplasty of first metatarsophalangeal joint.

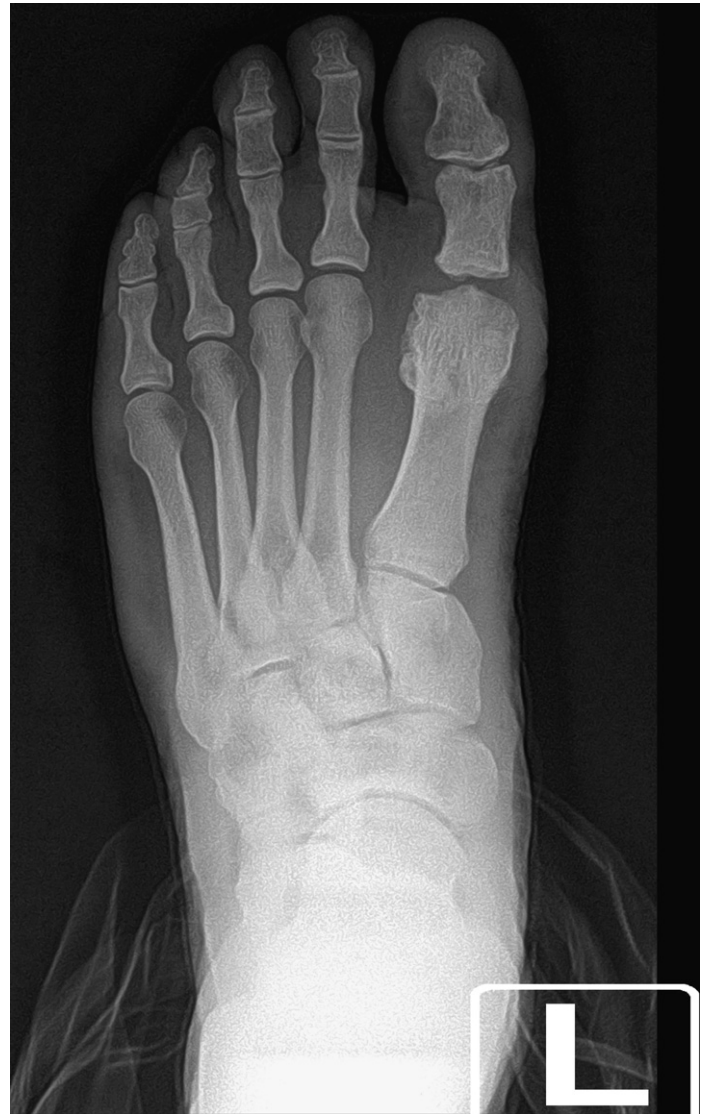

Fig. 3. Resectional arthroplasty. Postoperative dorsal-plantar radiographic view demonstrating result of resectional arthroplasty of first metatarsophalangeal joint.

withdrawn because of the lack of study progress and subject enrollment. The other site was withdrawn because multiple pages of data were either not collected or missing. The data collected from these sites were not used in the final analysis. Two replacement sites were added according to the same criteria as listed. After an interim power analysis was conducted, an additional investigational site was added to increase the power of the study. Hence, the data from 6 sites were used for the final statistical analysis.

Each investigative site was provided a detailed study binder that outlined the specific instructions for proper study execution and data collection. The investigative sites were provided a stipend to participate in the present study. All investigative sites received approval by the Western Institutional Review Board (Olympia, WA), which served as the centralized institutional review board for all participating investigational sites.

Surgical Technique

No standardized surgical technique was used for any of the 3 procedures. A range of fixation devices was used for the arthrodesis procedure, including the use of wires, screws, and/or plates. The type of hemi-implant used differed from surgeon to surgeon; however, all involved the use of a hemi-implant placed at the base of the proximal phalanx. The technique for the implantation of the hemi-implant also differed from surgeon to surgeon. The performance of the resectional arthroplasty was relatively consistent. However, the amount of the proximal phalanx removed and the type of tissue used for interposition differed from surgeon to surgeon.

Patients

The patients who underwent arthrodesis, hemi-implant arthroplasty, or resectional arthroplasty for the treatment of end-stage hallux rigidus, with a minimum follow-up period of 12 months, were recruited into the present study. The patients were identified through a review of charts for patients with grade 3 or 4 hallux rigidus using the Coughlin and Shurnas Classification System for Hallux Rigidus (8). The patients were contacted by telephone and asked to return to their surgeon's (site investigator) office to collect both subjective and objective information. The patients were excluded from the study if they had a history of seronegative or seropositive arthropathy. The patients were compensated for their participation.

Measurement Tools

Demographic information was collected, including age, gender, weight, height, postoperative time to follow-up, and type of procedure performed. Outcome measures were obtained from both the patient and the site investigator. The site investigator performed a radiographic and clinical evaluation specific to each procedure performed. The clinical evaluation included a physical examination of the surgical limb, and these findings were recorded by the site investigator. The physical examination included pain with palpation about the joint and forefoot and the relative position of the hallux. Radiographic examination included 3 weight bearing views (dorsal-plantar, lateral, and oblique), which were reviewed by the site investigator. The radiographic examination included noting any osseous changes around the joint, the relative position of the first

ray, and the position of the joint implant. Included in the site investigator evaluation was whether a suboptimal result required revisional surgery and what type of revisional surgery was conducted.

The subjects completed 2 patient-reported outcomes questionnaires assessing pain, function, and alignment/appearance. One of these questionnaires used the First Metatarsophalangeal Joint and First Ray Scoring Scale (patient questionnaire) of the ACFAS, which uses a 50-point scale divided into pain (30 points), functional capacity (15 points), and appearance (5 points) (Table 1) (30). The other outcomes questionnaire used was the modified Hallux Metatarsophalangeal-Interphalangeal Scale of the American Orthopedic Foot and Ankle Society (AOFAS), which uses a 100-point scale divided into pain (40 points), function (40 points), and alignment/cosmesis (20 points) (Table 2) (32,33).

Statistical Analysis

Differences in the demographic information among the 3 procedure groups was statistically analyzed using 1-way analysis of variance, chi-square, and Kruskal-Wallis tests. A comparison between the right and left legs was conducted using a related samples Wilcoxon test for patients with bilateral data points. The patient-reported outcome measures among the 3 procedure groups were statistically compared using a Kruskal-Wallis test. The results of the ACFAS and modified AOFAS subjective questionnaires were not normally distributed; therefore, the median scores were statistically compared using the Spearman's rank correlation coefficient. Statistical significance was defined at $p \leq .05$. The surgeon's clinical and radiographic evaluations were tabulated, but no statistical comparison was performed owing to the lack of consistency of findings among the 3 procedures. A power calculation was also conducted at a significance level of 0.05, power of 0.80, medium effect size of 0.25, and large effect size of 0.40. Using these limits, the sample size needed in each group to detect a medium effect was 53, with 22 patients needed to detect a large effect. All statistical calculations were performed using Statistical Package for Social Sciences, version 14.0, for Windows (Armonk, NY).

Results

A total of 158 patients (105 females and 53 males) were enrolled in the present study and underwent 51 arthrodesis, 52 hemi-implant, and 55 resectional arthroplasty procedures (Table 3). The mean age was 60.5 ± 9.7 (range 36 to 84) years for the arthrodesis group, 61.4 ± 7.5 (range 45 to 85) years for the hemi-implant group, and 64.3 ± 11.3 (range 39 to 92) years for the arthroplasty group. No significant difference was found in the mean age ($p = .11$) or number of patients in each group ($p = .16$) for the 3 procedures. The height and weight measurements were converted into the body mass index (BMI). A significant difference was found in the BMI among the 3 groups ($p = .007$). Those who underwent a hemi-implant procedure had

Table 1
First Metatarsophalangeal Joint and First Ray Scoring Scale (patient questionnaire) of the American College of Foot and Ankle Surgeons

Parameter	Degree	Score
Pain: Over the past month, how much has your foot pain limited your daily activities?		
	I have no pain with normal activities	30
	I have slight pain or occasional pain but no limitation of activities	22
	I have moderate pain limiting some activities	14
	I have pain and significant limitation of activities	6
	I have severe pain that limits almost all activity	0
Appearance: How would you rate the appearance of your big toe joint? (31)		
	I like it very much	5
	I mostly like it	4
	I'm not sure either way—neutral	3
	I mostly do not like it	2
	I definitely dislike it	0
Functional capacities: How frequently do you have pain wearing shoes?		
	I am able to continuously wear any type of shoe	15
	I am able to wear any type of shoe most of the time	10
	I am able to wear only walking, athletic, or casual shoes	5
	I am able to wear only special order, orthopedic or custom-made shoes	0

Adapted from Zlotoff HJ, Christensen JC, Mendicino RW, Schuberth JM, Schwartz NH, Thomas JL, et al. ACFAS Universal Foot and Ankle Scoring System: First Metatarsophalangeal Joint and First Ray (module 1). J Foot Ankle Surg 41:2–5, 2002.

Table 2
Modified Hallux Metatarsophalangeal-Interphalangeal Scale of the American Orthopedic Foot and Ankle Society

Parameter	Degree	Score
Pain		
	None	40
	Mild	30
	Occasional	20
	Severe, almost always present	0
Function		
Activity limitations		
	No limitations	10
	No limitations of daily activities, such as employment responsibilities or recreational activities	7
	Limited daily and recreational activities	4
	Severe limitation of daily and recreational activities	0
Footwear requirements		
	No restrictions	10
	Restricted to sneakers, wide shoes	5
	Restricted to modified shoes	0
Range of motion		
	Completely satisfied	10
	Nonpainful, limited motion	5
	Painful, restricted motion	0
Calluses		
	None or present and nonpainful	5
	Painful	0
Swelling		
	None	5
	Slight	3
	Almost always present	0
Alignment/cosmesis		
	Good, pleased	20
	Fair	10
	Poor, unhappy	0

Modified scale adapted from Roukis et al (33), with permission; original scale from Kitaoka et al (32).

a statistically significantly lower BMI than those who underwent arthrodesis ($p = .050$) or arthroplasty ($p = .007$). The median postoperative interval was 194 weeks for the arthrodesis group, 188 weeks for the hemi-implant group, and 124 weeks for the resectional arthroplasty group. Overall, the median postoperative follow-up period was 159 weeks. The median postoperative follow-up period was not significantly different among the 3 procedure groups ($p = .052$).

Statistical calculations were performed to detect differences in the patient-reported outcome scores. No statistically significant difference was observed between the right and left limbs for the cumulative outcome scores for either the ACFAS or the modified AOFAS scores ($p = .514$ and $p = .689$ respectively). The median total ACFAS score was 42 for the arthrodesis procedure group, 42 for the hemi-implant procedure group, and 44 for the resectional arthroplasty procedure group (Table 4). No statistically significant difference was found among the 3 procedure groups ($p = .642$). The median total modified AOFAS score was 90 for the arthrodesis procedure group, 80 for the hemi-implant group, and 92 for the resectional arthroplasty procedure group. No statistically significant difference was found among the 3 procedure groups ($p = .138$). The ACFAS scores were multiplied by 2 to compare these scores to the modified AOFAS scores. The correlation coefficient between the ACFAS and AOFAS scores was 0.783, which was statistically significant, revealing a moderate to high correlation between the results of the 2 scoring scales ($p < .001$).

The surgeon's clinical and radiographic findings were tabulated (Table 5). The following findings were identified in the arthrodesis group: metatarsalgia (9.8%), nonunion (7.8%), malalignment (7.8%), hallux interphalangeal joint pain (3.9%), and delayed union (2%)

Table 3
Statistical description for the 3 procedure groups

Variable	Arthrodesis (n = 51)	Hemi-Implant (n = 52)	Resectional Arthroplasty (n = 55)	p Value
Age (y)	60.5 ± 9.7	61.4 ± 7.5	64.3 ± 11.3	.11
Gender (n)				.16
Female	31	32	42	
Male	20	20	13	
BMI (kg/m ²)	28.1 ± 5.6	25.6 ± 3.8	28.7 ± 5.8	.007
BMI (95% CI)	26.5–29.6	24.6–26.7	27.1–30.3	
Median postoperative period (wk)	194	188	124	0.052

Age and BMI calculated as mean ± standard deviation.

Tukey's highly significant difference post hoc test conducted on BMI data to detect where the difference lies between groups.

Statistical comparison among 3 groups for postoperative period calculated using nonparametric test (Kruskal-Wallis).

Arthrodesis vs. hemi-implant, $p = .050$; hemi-implant vs. resectional arthroplasty, $p = .007$; and resectional arthroplasty vs. arthrodesis, $p = .801$.

Abbreviations: BMI, body mass index; CI, confidence interval.

(Table 5). Three revision surgeries were performed, with 2 fusions using a bone graft and 1 fusion not requiring a bone graft. The following findings were identified in the hemi-implant group: bony overgrowth into the joint (28.8%), radiolucency around the implant (19.2%), migration of the implant (15.4%), dorsal drift of the hallux (11.5%), cystic changes around the implant (7.7%), metatarsalgia (7.7%), elevation of the first ray (5.8%), subsidence of the implant (1.9%), and sub-first metatarsal pain (1.9%). Two revision surgeries were performed and involved the removal of the implant with resectional arthroplasty performed in both cases. The following findings were identified in the arthroplasty group: floating hallux (30.9%), metatarsalgia (14.5%), sesamoiditis (5.5%), and remodeling/regrowth at the head of the first metatarsal (3.6%). No revision surgeries were performed.

Discussion

To our knowledge, this is the first multicenter study comparing the long-term outcomes for the 3 most commonly performed surgical procedures for the treatment of end-stage hallux rigidus. Our results indicate that all 3 procedures result in high overall patient subjective scores at follow-up of an average of approximately 3 years. Furthermore, there did not appear to be a procedure selection bias based on the patient's age. The BMI of the hemi-implant patients was significantly lower statistically than that of the other 2 procedure groups. However, we cannot conclude that the surgeon selected patients with a lower BMI to have a hemi-implant procedure performed.

Owing to the long-term nature of the present study, there was significant time to observe any complications. The complications we observed in our study are consistent with those reported in the published data for each procedure. The most prevalent complication for arthrodesis was a combined 9.8% rate for nonunions and delayed unions. This correlates with the reported rates of nonunion for primary arthrodesis of 2% to 13% (34–37). The hemi-implant arthroplasty group revealed an osseous overgrowth rate of 28.8% and

Table 4
Median subject-reported ACFAS and modified AOFAS scores for 3 procedures

Questionnaire	Arthrodesis (n = 51)	Hemi-Implant (n = 52)	Resectional Arthroplasty (n = 55)	p Value
ACFAS	42	42	44	.64
Modified AOFAS	90	80	92	.14

Abbreviations: ACFAS, American College of Foot and Ankle Surgeons; AOFAS, American Orthopedic Foot and Ankle Society.

Table 5
Results of surgeons' clinical and radiographic examination

Findings	N (%)
Arthrodesis (n = 51)	
Metatarsalgia	5 (9.8)
Nonunion	4 (7.8)
Malalignment	4 (7.8)
Interphalangeal joint pain	2 (3.9)
Delayed union	1 (2)
Revisional surgery and type	
Fusion with bone graft	2
Fusion without bone graft	1
Hemi-implant (n = 52)	
Bony overgrowth into joint	15 (28.8)
Radiolucency around implant	10 (19.2)
Migration of implant	8 (15.4)
Dorsal drift of hallux	6 (11.5)
Metatarsalgia	4 (7.7)
Cystic changes around implant	4 (7.7)
Elevation of first ray	3 (5.8)
Subsidence of implant	1 (1.9)
Sub-first metatarsal pain	1 (1.9)
Revisional surgery and type	
Keller arthroplasty	2
Resectional arthroplasty (n = 55)	
Floating hallux	17 (30.9)
Metatarsalgia	8 (14.5)
Sesamoiditis	3 (5.5)
Regrowth/remodeling	2 (3.6)
Revisional surgery and type	0

Clinical and radiographic findings for each procedure type listed in order from most common to least common.

lucency about the implant rate of 19.2%. These observations did not necessitate the need for removal and did not correlate with a lower patient satisfaction score compared with the other procedure groups. These findings are also consistent with those from other published studies who have questioned the use of joint implants for the first MTPJ (38–45). Within the resectional arthroplasty group, we observed “floating hallux,” which occurred in 30.9% of the cases, with lesser metatarsalgia in 14.5% of the cases. These rates are lower than from other published reports, which have reported up to 79% of postoperative floating toe and 57.9% complaining of metatarsalgia (46–48).

Beertema et al (25) retrospectively compared the long-term outcome (mean of 7 years) of 74 patients who underwent cheilectomy, resectional arthroplasty, or arthrodesis. They reported that resectional arthroplasty yielded better results in earlier stages of hallux rigidus than did arthrodesis. Additionally, 33% of subjects reported a limited walking distance in the arthrodesis group compared with 14% of the subjects in the resectional arthroplasty group reporting a limited walking distance. This is in contrast to a prospective, randomized study by O'Doherty et al (26), which compared resectional arthroplasty versus arthrodesis in 82 subjects with a follow-up of at least 2 years. They reported no difference in patient satisfaction, relief of pain, improvement in walking distance, or reduction in footwear problems between the 2 groups. They went on to recommend resectional arthroplasty in older patients with hallux rigidus because of its technical simplicity. Our results indicate that age was not a factor in procedure selection and did not negatively affect patient satisfaction.

Gibson and Thomason (49) published a prospective, randomized, controlled trial directly comparing the outcomes between implant arthroplasty and arthrodesis. A total of 63 patients with end-stage hallux rigidus were randomized into an arthrodesis group (circlage wire and pinning) or an implant arthroplasty group (unconstrained 2-component system). Pain, function, radiographic alignment, patient satisfaction, clinical changes, and adverse events were measured. At 12 and 24 months, the arthrodesis group was superior to the implant

arthroplasty group with respect to pain, function, and alignment. The cost of the arthrodesis was also reported as lower. However, there are significant issues with their study. For example, the randomization was marred by bilateral assignment. Furthermore, the patients were not accounted for in all measurements. There are other important considerations as well. The first is that significant pain relief was reported in both groups at the 2-year follow-up period. Ultimately, pain relief is the goal for any joint destructive procedure. That study clearly demonstrated that implant arthroplasty significantly decreased pain. Second, the cost analysis might not be accurate because screw and/or plate fixation is the most predominant type of fixation currently in use for first MTPJ fusions. Therefore, these costs would be greater than the circlage wire and pin fixation used in their study (26). We did not perform a cost analysis and hence cannot conclude that any of the 3 procedures performed is more or less costly. Cost is a consideration in procedure selection (50). This is certainly true if the outcome of 1 procedure was clearly inferior to another. The results from our study did not reveal any statistically significant difference in the patient satisfaction scores between the arthrodesis group and hemi-implant group.

Raikin et al (51) published a retrospective study involving 46 subjects who had undergone either hemi-metallic implant arthroplasty or joint fusion. All hemi-implant arthroplasties were performed by 1 surgeon and the fusions, using 2-crossed screws, were performed by another surgeon. The investigators concluded that arthrodesis of the first MTPJ was more predictable for reduction of pain and restoring function than the implant arthroplasty group. However, both groups reported a decrease in pain. Again, this is in contrast to our results, which showed no difference in patient outcome scores between hemi-metallic implant arthroplasty and arthrodesis.

Maffulli et al (52) conducted a quantitative, systematic literature review of surgical procedures for the treatment of hallux rigidus, including arthrodesis, hemi-implant arthroplasty, and resectional arthroplasty. They concluded that “the heterogeneity in terms of study design, length of follow-up, classification grading systems, radiological and clinical findings did not allow [us] to compare extracted data.” Despite those limitations, they found that the 3 procedures examined in our study had comparable reported success rates in the published data they reviewed. In our study, we used the same classification system, the subjective outcome scoring scale, and radiographic and clinical parameters. We also came to the same conclusion that the results are comparable, regardless of the selected procedure.

Our study had several limitations. First, the retrospective nature of our study design did not allow for preoperative (baseline) score comparisons or pre- versus postoperative score comparisons. Therefore, it is possible that the preoperative scores could have been lower for 1 group versus another. This could have skewed the results in favor of 1 procedure over another. However, because we found no difference in the subjective post-operative outcome scores among the 3 procedures, the use of preoperative scores does not appear to be as relevant. If differences had been found in the postoperative scores among the 3 procedures, then certainly the initial preoperative scores could have biased the results. Furthermore, we cannot conclude anything regarding the degree of improvement from preoperatively to postoperatively. Again, this is a significant limitation for a retrospective study design. Second, the surgical technique was not standardized for any of the 3 procedures. Owing to the retrospective, multicenter study design, procedure standardization would have been impossible. Our study reflects a more “real world” design in which there are differences in surgical technique between surgeons and geographic location. Despite the differences in the surgical technique used from surgeon to surgeon, the long-term outcomes of pain, function, and alignment/appearance were not significantly

different statistically, regardless of the surgical procedure selected. Finally, procedure selection bias might have influenced the results. A surgeon might have selected a particular procedure according to the patient's individual expectations, the surgeon's experience with a particular procedure, and multiple other factors. This bias is inherent to a multicenter/multisurgeon study design and cannot be entirely circumvented. Again, we believe that the results of the present study allows for a greater degree of generalizability and applicability, because our results showed no difference in the outcome scores despite the factors that might have differed from patient to patient and surgeon to surgeon.

Conclusion

The results of our study indicate similar long-term patient satisfaction scores for treatment of end-stage hallux rigidus with arthrodesis, hemi-implant arthroplasty, and resectional arthroplasty. Furthermore, procedure selection does not appear to be related to the age of the patient. The surgeon should also discuss the commonly occurring long-term findings of each selected procedure with the patient. There are multiple factors involved in the selection of the most appropriate procedure for the treatment of end-stage hallux rigidus. The bone quality, ambulatory and physical demands, desires of the patient for joint motion, and surgeon experience and knowledge of outcomes, all play a critical role in proper procedure selection.

Acknowledgment

We acknowledge Kim Cooper, PhD, at Midwestern University, Glendale Arizona for his statistical analysis and support.

References

- Grady JF, Axe TM, Zager EJ, Sheldon LA. A retrospective analysis of 772 patients with hallux limitus. *J Am Podiatr Med Assoc* 92:102–108, 2002.
- Coughlin MJ, Shurnas PS. Hallux rigidus: demographics, etiology, and radiographic assessment. *Foot Ankle Int* 24:731–743, 2003.
- Bouaicha S, Ehrmann C, Moor BK, Maquieira GJ, Espinosa N. Radiographic analysis of metatarsus primus elevatus and hallux rigidus. *Foot Ankle Int* 31:807–814, 2010.
- Flavin R, Halpin T, O'Sullivan R, FitzPatrick D, Ivankovic A, Stephens MM. A finite-element analysis study of the metatarsophalangeal joint of the hallux rigidus. *J Bone Joint Surg Br* 90:1334–1340, 2008.
- Beeson P, Phillips C, Corr S, Ribbans WJ. Hallux rigidus: a cross-sectional study to evaluate clinical parameters. *Foot (Edinb)* 19:80–92, 2009.
- Shurnas PS. Hallux rigidus: etiology, biomechanics, and nonoperative treatment. *Foot Ankle Clin* 14:1–8, 2009.
- Beeson P, Phillips C, Corr S, Ribbans W. Classification systems for hallux rigidus: a review of the literature. *Foot Ankle Int* 29:407–414, 2008.
- Coughlin MJ, Shurnas PS. Hallux rigidus: grading and long-term results of operative treatment. *J Bone Joint Surg Am* 85-A:2072–2088, 2003.
- Keiserman LS, Sammarco VJ, Sammarco GJ. Surgical treatment of the hallux rigidus. *Foot Ankle Clin* 10:75–96, 2005.
- Vanore JV, Christensen JC, Kravitz SR, Schubert JM, Thomas JL, Weil LS, Zlotoff HJ, Mendicino RW, Couture SD. Diagnosis and treatment of first metatarsophalangeal joint disorders. Section 2: hallux rigidus. *J Foot Ankle Surg* 42:124–136, 2003.
- Brage ME, Ball ST. Surgical options for salvage of end-stage hallux rigidus. *Foot Ankle Clin* 7:49–73, 2002.
- Broca P. Deformities of the anterior foot caused by various types of shoes. *Bull Soc Anat* 27:60–67, 1852.
- McKeever DC. Arthrodesis of the first metatarsophalangeal joint for hallux valgus, hallux rigidus, and metatarsus primus varus. *J Bone Joint Surg Am* 34-A:129–134, 1952.
- Kumar S, Pradhan R, Rosenfeld PF. First metatarsophalangeal arthrodesis using a dorsal plate and a compression screw. *Foot Ankle Int* 31:797–801, 2010.
- Wassink S, van den Oever M. Arthrodesis of the first metatarsophalangeal joint using a single screw: retrospective analysis of 109 feet. *J Foot Ankle Surg* 48:653–661, 2009.
- Maher AJ, Metcalfe SA. First MTP joint arthrodesis for the treatment of hallux rigidus: results of 29 consecutive cases using the foot health status questionnaire validated measurement tool. *Foot (Edinb)* 18:123–130, 2008.
- Coughlin MJ, Mann RA. Arthrodesis of the first metatarsophalangeal joint as salvage for the failed Keller procedure. *J Bone Joint Surg Am* 69:68–75, 1987.
- Machacek F Jr, Easley ME, Gruber F, Ritschl P, Trnka HJ. Salvage of a failed Keller resection arthroplasty. *J Bone Joint Surg Am* 86-A:1131–1138, 2004.

19. Vienne P, Sukthankar A, Favre P, Werner CM, Baumer A, Zingg PO. Metatarsophalangeal joint arthrodesis after failed Keller-Brandes procedure. *Foot Ankle Int* 27:894–901, 2006.
20. Swanson AB, Lumsden RM, Swanson GD. Silicone implant arthroplasty of the great toe: a review of single stem and flexible hinge implants. *Clin Orthop Relat Res* 142:30–43, 1979.
21. Giza E, Sullivan M, Ocel D, Lundeen G, Mitchell M, Frizzell L. First metatarsophalangeal hemiarthroplasty for hallux rigidus. *Int Orthop* 34:1193–1198, 2010.
22. Konkel KF, Menger AG, Retzlaff SA. Results of metallic hemi-great toe implant for grade iii and early grade iv hallux rigidus. *Foot Ankle Int* 30:653–660, 2009.
23. Sorbie C, Saunders GA. Hemiarthroplasty in the treatment of hallux rigidus. *Foot Ankle Int* 29:273–281, 2008.
24. Keller W. The surgical treatment of bunions and hallux valgus. *NY Med J* 80:741–742, 1904.
25. Beertema W, Draijer WF, van Os JJ, Pilot P. A retrospective analysis of surgical treatment in patients with symptomatic hallux rigidus: long-term follow-up. *J Foot Ankle Surg* 45:244–251, 2006.
26. O'Doherty DP, Lowrie IG, Magnussen PA, Gregg PJ. The management of the painful first metatarsophalangeal joint in the older patient: arthrodesis or Keller's arthroplasty? *J Bone Joint Surg Br* 72:839–842, 1990.
27. Hamilton WG, O'Malley MJ, Thompson FM, Kovatis PE. Roger Mann Award 1995: capsular interposition arthroplasty for severe hallux rigidus. *Foot Ankle Int* 18:68–70, 1997.
28. Sherman KP, Douglas DL, Benson MK. Keller's arthroplasty: is distraction useful? A prospective trial. *J Bone Joint Surg Br* 66:765–769, 1984.
29. Hahn MP, Gerhardt N, Thordarson DB. Medial capsular interpositional arthroplasty for severe hallux rigidus. *Foot Ankle Int* 30:494–499, 2009.
30. Zlotoff HJ, Christensen JC, Mendicino RW, Schuberth JM, Schwartz NH, Thomas JL, et al. ACFAS Universal Foot and Ankle Scoring System: First Metatarsophalangeal Joint and First Ray (module 1). *J Foot Ankle Surg* 41:2–5, 2002.
31. Cook JJ, Cook EA, Rosenblum BI, Landsman AS, Roukis TS. Validation of the American College of Foot and Ankle Surgeons scoring scales. *J Foot Ankle Surg* 50:420–429, 2011.
32. Kitaoka HB, Alexander IJ, Adelaar RS, Nunley JA, Myerson MS, Sanders M. Clinical rating systems for the ankle-hindfoot, midfoot, hallux, and lesser toes. *Foot Ankle Int* 15:349–353, 1994.
33. Roukis TS, Jacobs PM, Dawson DM, Erdmann BB, Ringstrom JB. A prospective comparison of clinical, radiographic, and intraoperative features of hallux rigidus: short-term follow-up and analysis. *J Foot Ankle Surg* 41:158–165, 2002.
34. Bennett GL, Kay DB, Sabatta J. First metatarsophalangeal joint arthrodesis: an evaluation of hardware failure. *Foot Ankle Int* 26:593–596, 2005.
35. Bennett GL, Sabetta J. First metatarsophalangeal joint arthrodesis: evaluation of plate and screw fixation. *Foot Ankle Int* 30:752–757, 2009.
36. Goucher NR, Coughlin MJ. Hallux metatarsophalangeal joint arthrodesis using dome-shaped reamers and dorsal plate fixation: a prospective study. *Foot Ankle Int* 27:869–876, 2006.
37. Ellington JK, Jones CP, Cohen BE, Davis WH, Nickisch F, Anderson RB. Review of 107 hallux MTP joint arthrodesis using dome-shaped reamers and a stainless-steel dorsal plate. *Foot Ankle Int* 31:385–390, 2010.
38. Ess P, Hamalainen M, Leppilahti J. Non-constrained titanium-polyethylene total endoprosthesis in the treatment of hallux rigidus: a prospective clinical 2-year follow-up study. *Scand J Surg* 91:202–207, 2002.
39. Freed JB. The increasing recognition of medullary lysis, cortical osteophytic proliferation, and fragmentation of implanted silicone polymer implants. *J Foot Ankle Surg* 32:171–179, 1993.
40. Fuhrmann RA, Wagner A, Anders JO. First metatarsophalangeal joint replacement: the method of choice for end-stage hallux rigidus? *Foot Ankle Clin* 8:711–721, 2003. vi.
41. Konkel KF, Menger AG. Mid-term results of titanium hemi-great toe implants. *Foot Ankle Int* 27:922–929, 2006.
42. Mondul M, Jacobs PM, Caneva RG, Crowhurst JA, Morehead DE. Implant arthroplasty of the first metatarsophalangeal joint: a 12-year retrospective study. *J Foot Surg* 24:275–279, 1985.
43. Papagelopoulos PJ, Kitaoka HB, Ilstrup DM. Survivorship analysis of implant arthroplasty for the first metatarsophalangeal joint. *Clin Orthop Relat Res* 302:164–172, 1994.
44. Pulavarti RS, McVie JL, Tulloch CJ. First metatarsophalangeal joint replacement using the bio-action great toe implant: intermediate results. *Foot Ankle Int* 26:1033–1037, 2005.
45. Vanore J, O'Keefe R, Pikscher I. Silastic implant arthroplasty: complications and their classification. *J Am Podiatr Assoc* 74:423–433, 1984.
46. Schenk S, Meizer R, Kramer R, Aigner N, Landsiedl F, Steinboeck G. Resection arthroplasty with and without capsular interposition for treatment of severe hallux rigidus. *Int Orthop* 33:145–150, 2009.
47. Ozan F, Bora OA, Filiz MA, Kement Z. Interposition arthroplasty in the treatment of hallux rigidus. *Acta Orthop Traumatol Turc* 44:143–151, 2010.
48. Love TR, Whynot AS, Farine I, Lavoie M, Hunt L, Gross A. Keller arthroplasty: a prospective review. *Foot Ankle* 8:46–54, 1987.
49. Gibson JN, Thomson CE. Arthrodesis or total replacement arthroplasty for hallux rigidus: a randomized controlled trial. *Foot Ankle Int* 26:680–690, 2005.
50. Hyer CF, Glover JP, Berlet GC, Lee TH. Cost comparison of crossed screws versus dorsal plate construct for first metatarsophalangeal joint arthrodesis. *J Foot Ankle Surg* 47:13–18, 2008.
51. Raikin SM, Ahmad J, Pour AE, Abidi N. Comparison of arthrodesis and metallic hemiarthroplasty of the hallux metatarsophalangeal joint. *J Bone Joint Surg Am* 89:1979–1985, 2007.
52. Maffulli N, Papalia R, Palumbo A, Del Buono A, Denaro V. Quantitative review of operative management of hallux rigidus. *Br Med Bull Epub*, 2011 Jan 14.